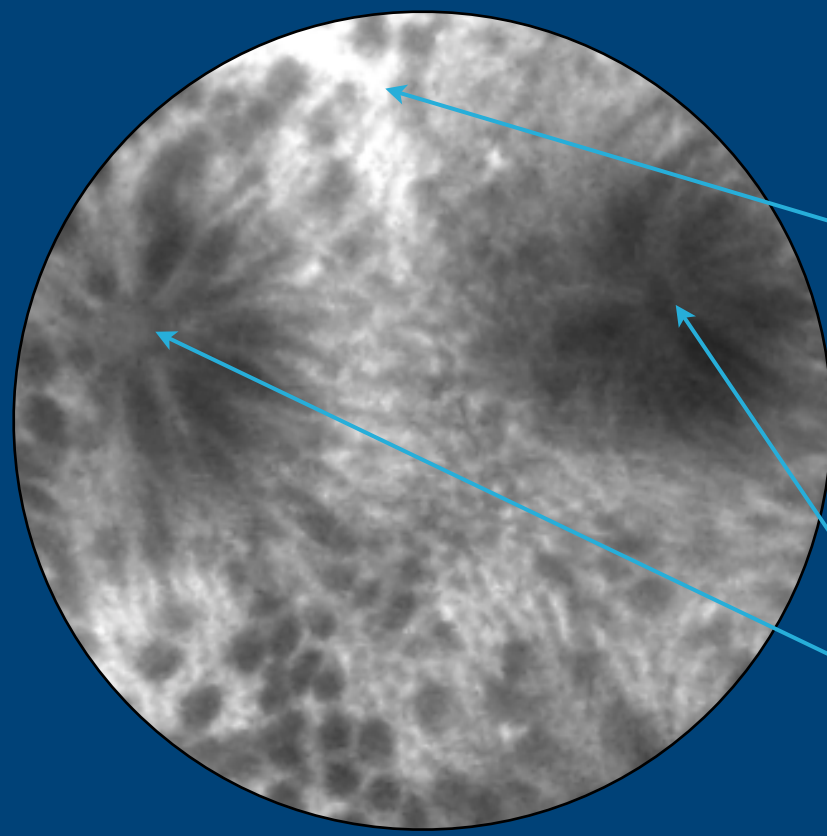
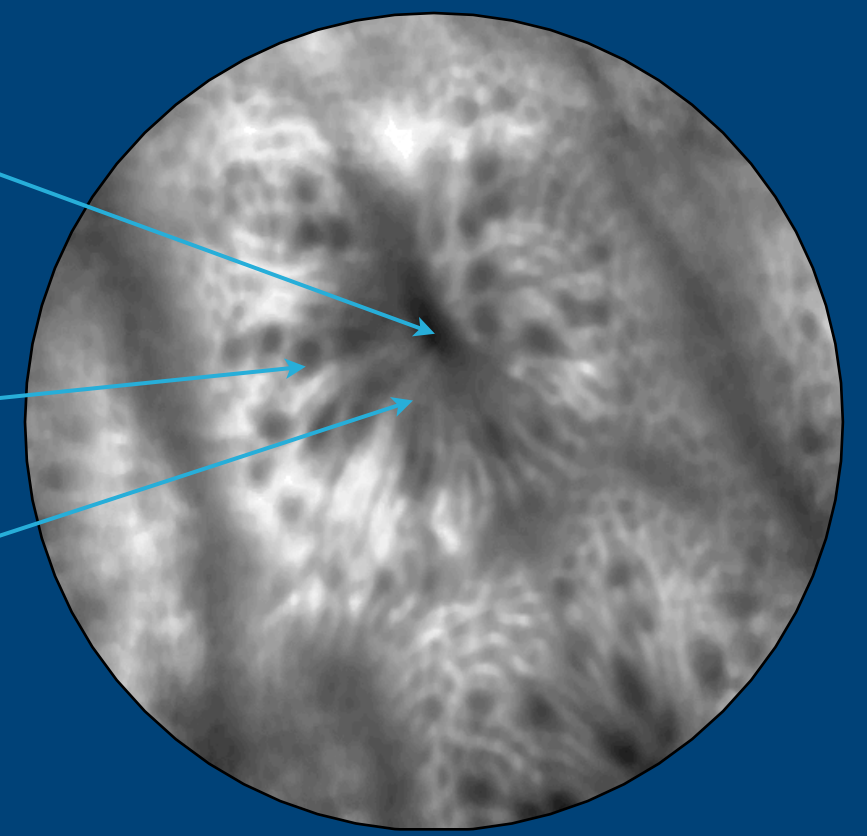


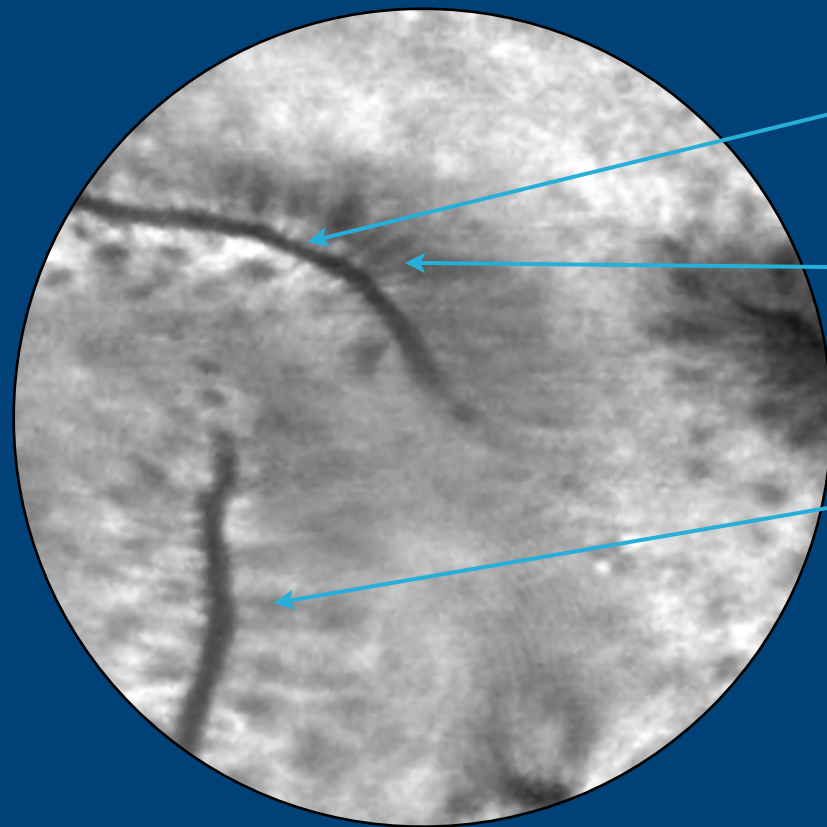
## HEALTHY COLON



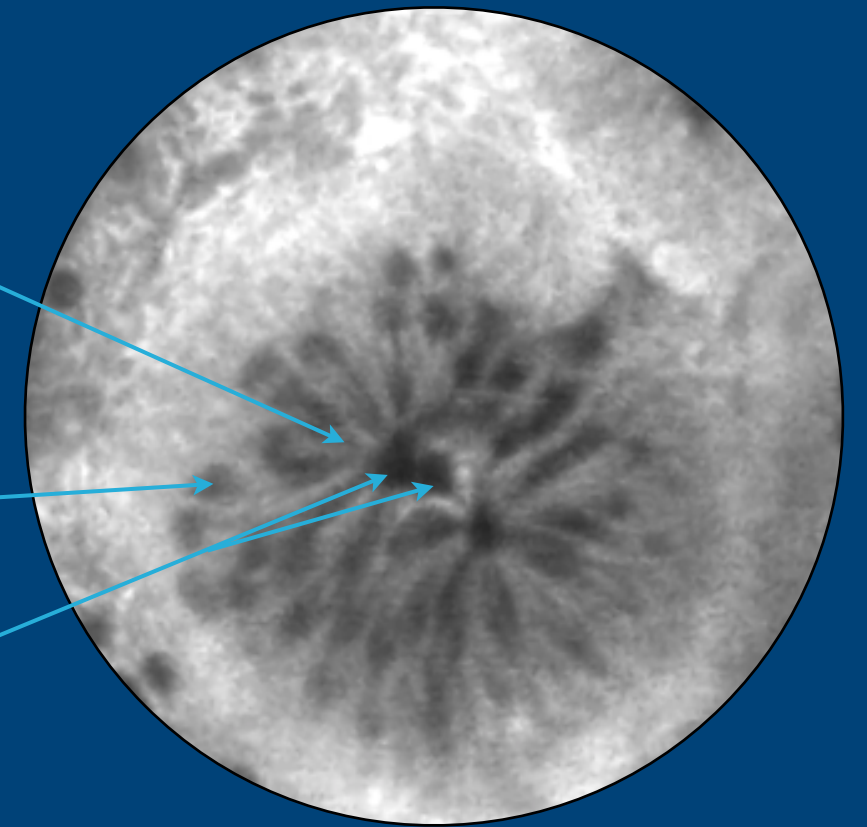
- Crypt lumen
- Blood vessels
- Goblet cells
- Epithelial cells
- Regular crypts



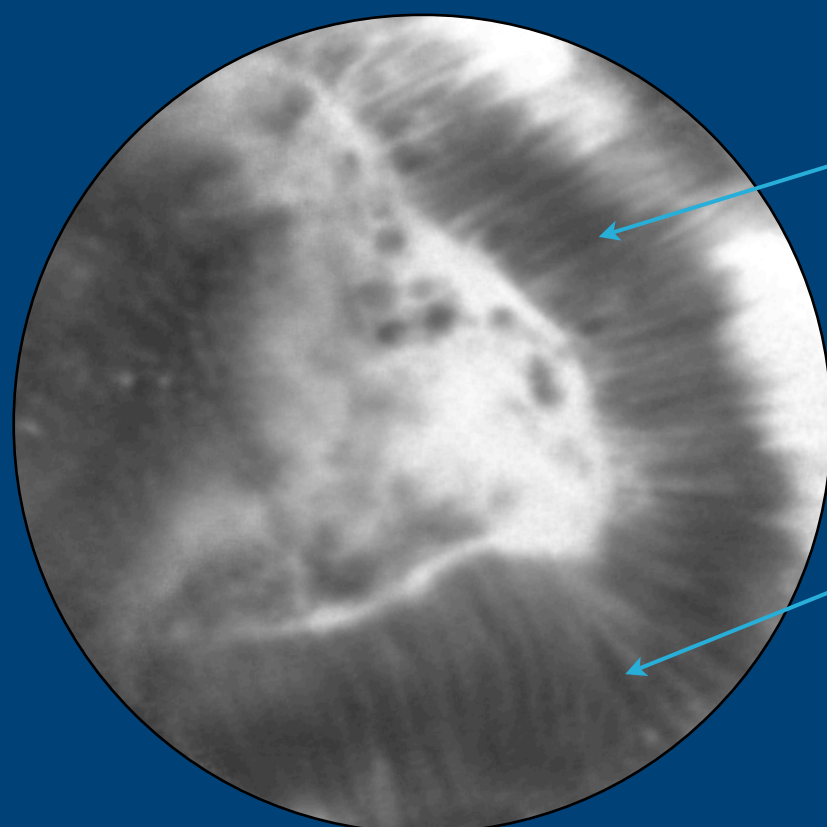
## HYPERPLASTIC COLONIC POLYPS



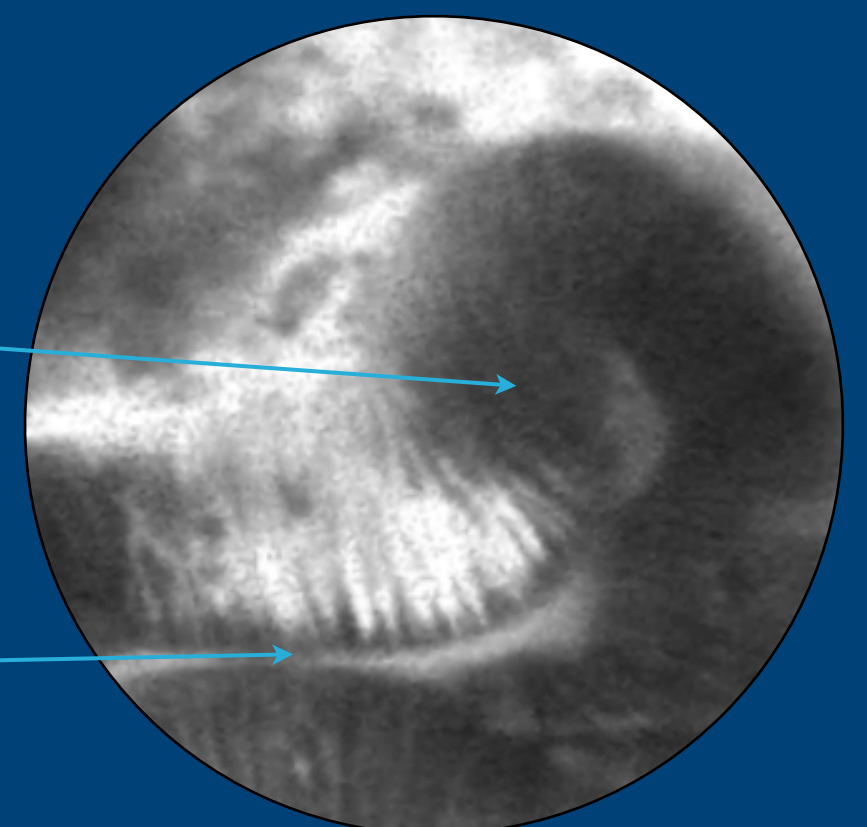
- Star-shaped luminal crypt openings
- Regular crypts and epithelium surrounding the lesion
- Normal goblet cells distribution
- Tortuous glands appearing doubled



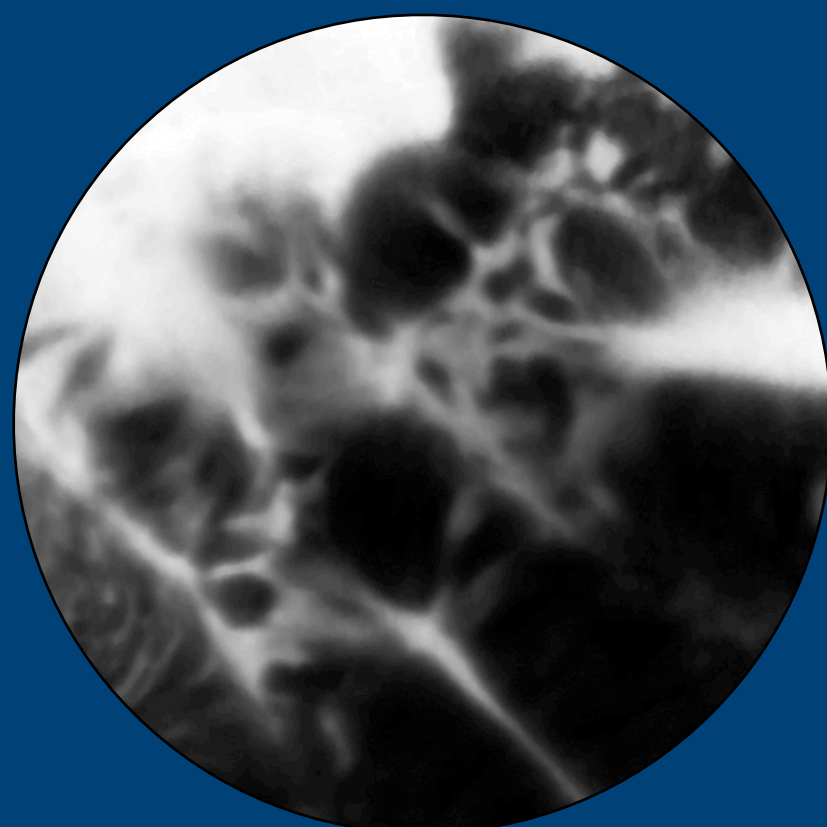
## ADENOMATOUS COLONIC POLYPS



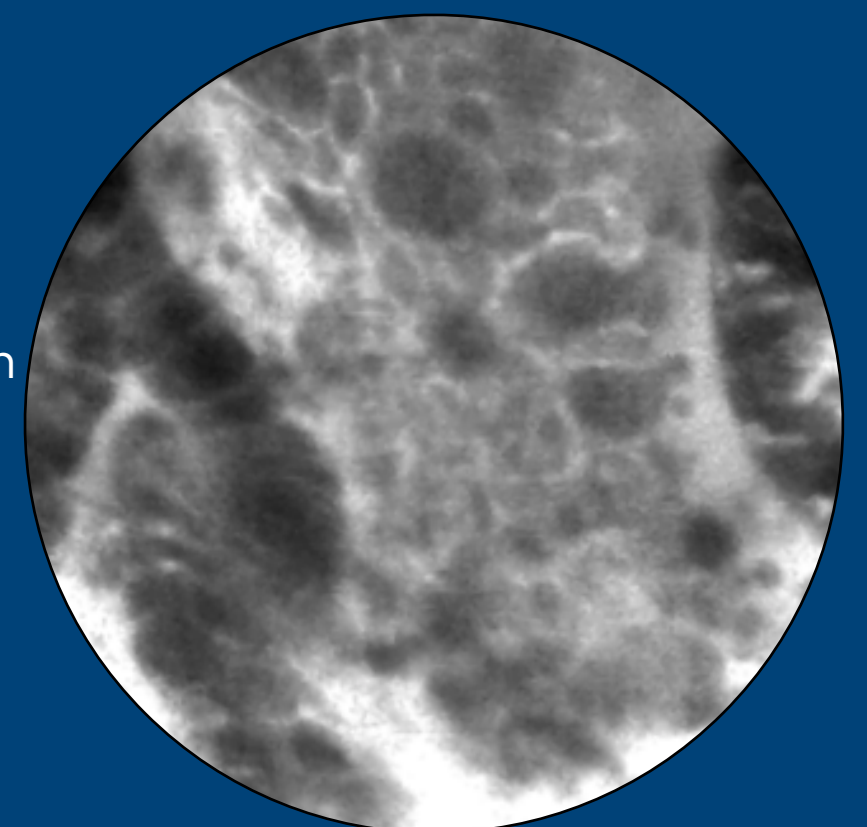
- Tubular and villous structures
- Thickening of epithelial lining
- Dark cells
- Distorted or elongated crypts



## ADENOCARCINOMA



- Complete disorganization and loss of structures in the tissue



# Optical Biopsy in the lower GI tract

